

Case Report

Left atrial myxoma and transient ischemic attack: case report

Michelle Franco Macedo de Lima¹, Nathália Varano¹, Omar Pereira de Almeida Neto², David de Souza Mendes³

¹Cardiology Nursing Practitioner Fellowship, Federal University of Uberlandia, Uberlândia 38400-142, MG, Brazil;

²Cardiovascular Science, Department of Medicine, Federal University of Uberlandia, Uberlândia 38400-902, MG, Brazil; ³Federal University of Health Science of Porto Alegre, Porto Alegre 90050-170, MG, Brazil

Received June 21, 2021; Accepted July 14, 2021; Epub August 15, 2021; Published August 30, 2021

Abstract: Cardiac tumors are rare and myxomas are the most prevalent among them. Although it presents benign histology, they may be the cause of severe consequences due to intracardiac location. Nonspecific manifestations may hinder the diagnosis, which can lead to complications, such as changes in cardiac dynamics, thromboembolic events and death. This paper presents a case report of a patient in the emergency department of a high complexity hospital in Minas Gerais State, Brazil, with a clinical history of angina and 7 previous Transient Ischemic Attack (TIA), besides aphasia, right hemiparesis, dysarthria, and mouth deviation. Submitted to transesophageal echocardiography, she was diagnosed with left atrial myxoma. For the treatment of myxoma, a surgical approach was used to resect the myxoma in the left atrium. The standard surgical approach was through a median sternotomy. Cardiopulmonary bypass (CPB) with aortic and bicaval cannulation and moderate hypothermia was used. Myocardial protection was achieved by cold antegrade blood cardioplegia. The patient had notable characteristics for the diagnosis, especially the previous occurrence of seven episodes of TIA. The importance of correct clinical investigation (anamnesis, general and specific physical examination and imaging tests) is notable and a fundamental tool for the diagnosis and early treatment of neoplasia, providing good clinical outcomes.

Keywords: Cardiac tumor, atrial myxoma, transient ischemic attack, case report

Introduction

Primary cardiac tumors are uncommon and among them, myxomas are the most frequent. They are often identified accidentally or when they manifest themselves by symptoms that lead the patient to seek healthcare in an emergency room. The most common symptoms are dyspnea, angina and syncope, but other nonspecific manifestations may also occur, such as weight loss. Patients with cardiac myxoma tend to show signs contemplated by a classical triad: constitutional, cardiac and embolic [1].

Myxomas mainly affect women between 30 and 60 years of age, present benign histology in 75% of cases, and commonly present signs that can be identified by echocardiography [2]. Myxomas are more frequently located in the left atrium, but they may also be identified

attached to the heart valves, in the ventricles or even indistinctly, in multiple locations [1].

Clinical signs, manifestations and symptoms resulting from cardiac myxoma depend on the location, size and mobility of the tumor. Younger and male patients tend to express specific neurological symptoms, while women tend to have systemic symptoms [3].

Cardiac symptoms occur due to obstruction of blood flow, resulting in syncope, pulmonary edema and dyspnea [4]. A previous study comparing the location of the tumor showed that patients with left atrial myxoma are predisposed to have more severe dyspnea than those with tumor located on the right side [1].

The symptomatology of cardiac myxomas usually begins with neurological manifestations, particularly ischemic events, such as Transient

Myxoma and transient ischemic attack

Ischemic Attack (TIA) or stroke, especially among young patients without cardiovascular risk factors. Studies have identified unilateral sudden motor deficit as a frequent neurological symptom. Neurological manifestations of cardiac myxomas are usually due to cerebrovascular complications, and occur in 25-45% of cases [5]. Gil et al., point out that all young patients presenting stroke or TIA should be screened for atrial myxoma [4].

Studies show that coronary heart disease and conditions such as presence of left atrial myxoma may coexist. This shows the importance of echocardiographic examination. Echocardiography is an important test for the diagnosis and topographic characterization of primary cardiac tumor, such as size and location [6].

Moreover, echocardiography is of fundamental importance for the increase in the detection of cardiac. Myxomas with a smoother surface are usually larger and generate obstructive symptoms, while myxomas with irregular surface, such as roughness, can lead to embolic complications and require surgical intervention. In general, the surgery is curative, not impacting the patient's quality of life [7].

Trans-esophageal examination is more accurate than the transthoracic test [6]. Besides, a recent research reported that transthoracic echocardiography has a sensitivity of approximately 95% for detection, while trans-esophageal echocardiography has 100% sensitivity.

After diagnosing of cardiac myxoma, the best treatment is surgical resection. This procedure contributes to an excellent prognosis and as the tumor is histologically benign, death usually arise from obstruction, distal embolization or rhythm disorders [3]. Local recurrence is uncommon, but may be related to incomplete resection, multicentricity, and genetic conditions. Annual echocardiographic follow-up is recommended for a minimum of 4 years after resection [4].

This case report was related using the guideline CARE® as required to improve the quality of dates and presentation of text and outcomes. Besides, appropriate patient consent, was obtained to develop this case report.

Case report

History diseases and physical examination

Female patient, 62-year-old, smoker for more than 50 years, seeks the emergency department of a high complexity hospital in Minas Gerais State, Brazil, reporting sudden pain in the right hemithorax, without relieving or aggravating factors. She described the occurrence of seven Transient Ischemic Attack, and the last one occurred three weeks before and presented with aphasia, right hemiparesis, dysarthria and mouth deviation. Furthermore, claimed hyporexia and weight loss and reported seven other episodes of syncope and paresis in the last four years, which were diagnosed as not related to ischemic events. The patient reported regular use of: Clopidogrel 75 mg, Acetylsalicylic Acid 100 mg, Simvastatin 40 mg, Bisoprolol 5 mg and Quetiapine 25 mg.

In the primary evaluation, the patient's vital signs were: blood pressure of 100/50 mmHg, heart rate of 78 beats per minute, O₂ saturation of 95%, respiratory rate of 18 incursions per minute, axillar temperature of 36°C; and its complaint was chest pain.

Diagnoses and treatment

On an initial approach, the patient underwent systemic physical examination, electrocardiogram, multiple blood tests and chest x-ray.

There were no abnormalities on the physical examination-regular heart rate on auscultation, no audible murmurs, pulmonary auscultation with physiological vesicular murmur, no adventitious noises. The electrocardiogram presented sinus rhythm.

Blood tests revealed normal values on blood count, renal and hepatic functions. Blood gas analysis revealed increased arterial lactate (2.62 mmol/L-reference values: 0.36 to 0.75 mmol/l).

Increased vascular marking was seen on the chest x-ray, in addition to thickened interlobular septum and slightly increased bilateral vascular markings, which indicates neovascularization, suggestive of cardiac tumor (**Figures 1 and 2**). Due to these findings, the patient was

Myxoma and transient ischemic attack

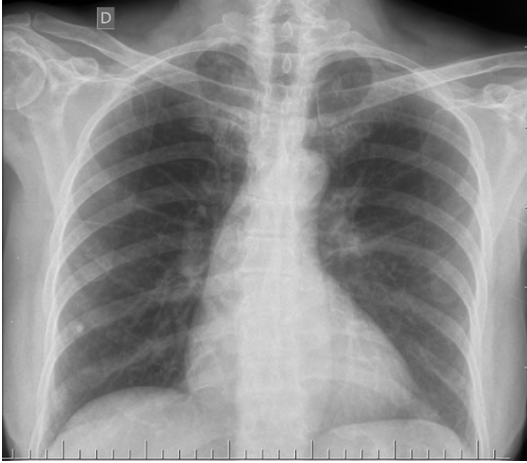


Figure 1. Chest x-ray anterior image, UFU Medical School Clinics Hospital, Brazil, 2021.

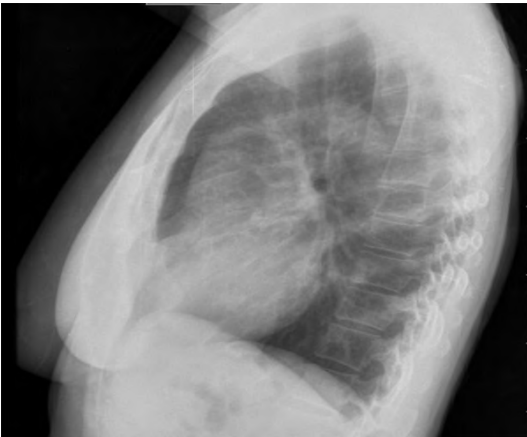

Figure 2. Chest x-ray image in profile, UFU Medical School Clinics Hospital, Brazil, 2021.

submitted to transesophageal echocardiography, which identified a peduncular mass in the basal septum, with irregular edges, and dimensions 4.9 cm × 2.9 cm in the left atrium.

After hospital admission to investigate the mass found, a coronary angiography was performed in radial technique, which revealed proximal calcification and atherosclerotic plaque obstructing 40% of the fbw in the middle third of the anterior descending artery (**Figure 3**), evidencing coexistence of coronary disease and the presence of the left atrial myxoma.

After 24 hours of hospitalization, a new transesophageal echocardiogram was performed and it confirmed the existence of a heteroge-

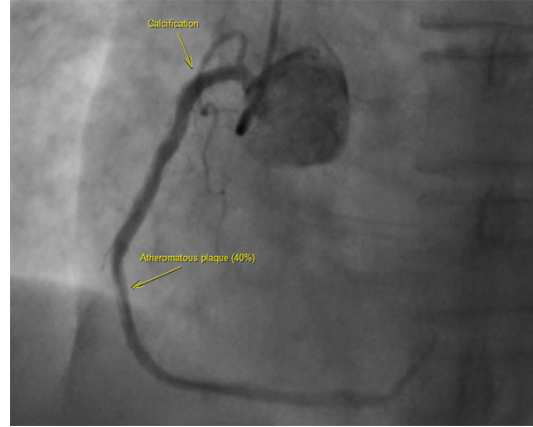


Figure 3. Coronary angiography imaging by radial technique, UFU Medical School Clinics Hospital, Brazil, 2021.

neous mass, with irregular, mobile surface, inside the left atrium with dimensions of 2.8 cm × 4.6 cm, pull in left ventricle through the mitral valve causing dynamic obstruction, suggestive of myxoma. The new echocardiogram also demonstrated a moderate volumetric increase in the left atrium, resulting from the overload caused by the presence of myxoma associated with mild mitral insufficiency.

Since the curative treatment of a myxoma relies on a surgical resection of the tumor, the patient underwent a median sternotomy, which is the standard surgical approach. The myxoma was accessed through the right atrium, on a transeptal incision. The surgical objective was to completely resect the tumor on its total thickness, also removing the attachment base and a cuff of interatrial septum to prevent recurrence. All four cardiac chambers were thoroughly explored for additional myxomas. Copious irrigation of the atria and ventricles with cold saline was done to eliminate any loose tumor fragments that might have been dislodged during removal of the tumor. The routine histopathological examination of the resected myxoma concluded that it was a grossly papillar neoplasm rich in myxoid and hyaline stroma with evident vascular system and showing isolated cells of starry aspect or forming small groups, confirmed the diagnosis of cardiac myxoma.

After surgery the patient was referred to the critical care unit postoperative recovery and discharged on the six days after the procedure.

Myxoma and transient ischemic attack

An anticoagulant, rivaroxaban, was prescribed to prevent future embolic events.

An interdisciplinary team composed by neurologists, radiologists, cardiologists, cardiothoracic surgeon, pulmonologist and nurses followed the patient providing care and avoiding complications, such as infectious endocarditis. An antiplatelet/anticoagulation therapy and antibiotic treatment were used in ambulatory.

In the fourth month of postoperative follow-up, the patient was normalization of the echocardiographic patterns of left and right chambers, as well as an increase in ejection fraction to 80% and mitral valve within the normal parameters.

Discussion

Primary cardiac tumors account for 5% of neoplasia. Atrial myxoma is the most frequent, with 45-50% of cases. Furthermore, most myxomas (80-90%) are in the left atrium. Right atrial myxomas tend to be more solid and sessile than left atrial myxomas, with a wider attachment to the atrial wall or septum. The clinical presentation depends on its location, since those located in the left atrium are associated with constitutional symptoms such as general malaise, anorexia, fever, arthralgia, weight loss, dyspnea and arrhythmias, syncope, edema of the lower limbs and chest pain [7].

The patient presented many symptoms but not all that can happen according to expertise of our team. Usually, others symptoms as respiratory difficulty on supine or lateral decubitus and while sleeping, dizziness, fainting, shortness of breath with activity and symptoms due to embolism of tumor material, bluish skin, Raynaud phenomenon, cough, fever, joint pain and weight loss without trying. In addition, some symptoms and signs can mimic mitral. In case of right atrial myxomas rarely produce symptoms until they have grown to be quite large.

Furthermore, laboratory studies are non-specific and non-diagnostic, and the abnormalities presented may include elevated erythrocyte sedimentation rate (ESR), elevated C-reactive protein and serum globulin levels, leukocytosis, anemia (may occur because of the mechanical destruction of erythrocytes by the tumor). Furthermore, serum interleukin-6 level may be

raised and can be used as a marker of recurrence. Cardiac myxomas form a very small percentage of clinical cardiac cases. Immediate surgical treatment is indicated in all patients. These tumors can be excised with a low rate of morbidity and mortality. The prognosis for patients after surgical resection tends to be excellent [5, 8, 9].

In about 25% to 45% of cases, myxoma may present with neurological symptoms, most of them as a stroke or TIA⁴. Neurological manifestations of cardiac myxomas are usually due to cerebrovascular complications from myxoma embolisms, and they may occur if the tumor neither diagnosed nor treated [5].

The presented case concerns a patient who, in addition to presenting hemiparesis and TIA as neurological manifestations, also reported cardiac symptoms as syncope and angina pectoris [10].

A TIA is characterized by reduced blood flow to the brain, reducing the amount of oxygen that reaches this organ. It leads to sudden transient neurological deficits and may present with a feeling of dizziness or vertigo, decreased strength in arms and legs (uni or bilateral), paresthesia, dysarthria, mouth deviation, headaches, nausea and vomiting, high blood pressure, lack of motor coordination and loss of consciousness. These symptoms have sudden onset and usually last less than 1 hour, disappearing completely so that it becomes unlikely to occur infarction when deficits disappear in this period of time. The risk of stroke after TIA is higher in the first 24 to 48 hours, so if one or the other is suspected, patients are usually hospitalized for screening [9].

However, most cases of TIA are due to embolism usually originating from the carotid or vertebral arteries. Seldom occur from insufficient perfusion due to hypoxemia as reported [9, 10].

The treatment of TIA aims to prevent strokes. Anticoagulants are indicated if there are cardiac sources of embolism since myxomas with irregular surface are more prone to embolism, by its possibility of fragmentation of myxoma as well as increasing of interactive areas [10].

Although the surgical team was concerned about possible complications (including arrhythmias, pulmonary edema, blockage of the

heart valves), the surgery was needed especially because the tumor caused heart failure symptoms and cerebral manifestations.

The high lactate dosage, marking poor perfusion, indicates a possible lactic acidosis that occurs due to decreased tissue oxygenation in cases of shock, left ventricular failure, and may be associated with diseases such as a neoplasm, for instance [11, 12].

Although case reports present many limitations, considering the rarity of the disease, it can improve scientific literature providing ideas to future studies using different kind of methodologies and improving neurovascular and cardiovascular area.

Conclusion

Although cardiac myxomas are benign tumors, they should be treated surgically as soon as possible after diagnosis because of embolic complications and obstructive signs, for instance, a TIA. An early surgical resection of cardiac myxoma is recommended in patients with not large territory cerebral infarct so as to prevent from the potential consequences.

Disclosure of conflict of interest

None.

Address correspondence to: Dr. Omar Pereira de Almeida Neto, Cardiovascular Science-Health Attention, Federal University of Uberlandia, Para Avenue, Uberlandia 38400-902, Minas Gerais State, Brazil. Tel: +55-34-3218-2000; E-mail: omar.almeida@ufu.br

References

- [1] Khan H, Chaubey S, Uzzaman MM, Iqbal Y, Khan F, Butt S, Deshpande R and Desai J. Clinical presentation of atrial myxomas does it differ in left or right sided tumor? *Int J Health Sci (Qassim)* 2018; 12: 59-63.
- [2] Veiga P, Bockler K, Ueda L and Porto I. Mixoma atrial: um relato de caso. *Fag Journal of Health (FJH)* 2020; 2: 159-164.
- [3] Karabinis A, Samanidis G, Khoury M, Stavridis G and Perreas K. Clinical presentation and treatment of cardiac myxoma in 153 patients. *Medicine* 2018; 97: 1-6.
- [4] Gil J, Marmelo B, Abreu L, Antunes H, dos Santos LF and Cabral JC. Silent cardiac tumor with neurological manifestations. *J Cardiol Cases* 2017; 15: 132-135.
- [5] Pérez Andreu J, Parrilla G, Arribas JM, García-Villalba B, Lucas JJ, Garcia Navarro M, Marín F, Gutierrez F and Moreno A. Neurological manifestations of cardiac myxoma: experience in a referral hospital. *Neurologia* 2013; 28: 529-534.
- [6] Ayesha J, Asma S, Adnan A and Muhammad F. Left atrial myxoma with TIA and coronary artery disease: a rare occurrence. *J Cardiovasc Dis* 2019; 82-84.
- [7] Cianciulli TF, Cozzarin A, Soumoulou JB, Saccheri MC, Méndez RJ, Beck MA, Gagliardi JA and Lax JA. Twenty years of clinical experience with cardiac myxomas: diagnosis, treatment, and follow-up. *J Cardiovasc Imaging* 2019; 27: 37-47.
- [8] Burgosa E, Bermúdez J and Chávez W. Atrial myxoma related with ischemic cerebrovascular event. *Med Clin* 2019; 151: 69-70.
- [9] Chong JY. Transient Ischemic Attack (TIA). *MSD Manual* 2020.
- [10] Wen XY, Chen YM, Yu LL, Wang SR, Zheng HB, Chen ZB, Ma L, Liao XP and Li QF. Neurological manifestations of atrial myxoma: a retrospective analysis. *Oncol Lett* 2018; 16: 4635-4639.
- [11] Aziz N, Zhao Q, Bry L, Driscoll DK, Funke B, Gibson JS, Grody WW, Hegde MR, Hoeltge GA, Leonard DG, Merker JD, Nagarajan R, Palicki LA, Robetorye RS, Schrijver I, Weck KE and Voelkerding KV. College of American Pathologists' laboratory standards for next-generation sequencing clinical tests. *Arch Pathol Lab Med* 2015; 139: 481-493.
- [12] Riley DS, Barber MS, Kienle GS, Aronson JK, von Schoen-Angerer T, Tugwell P, Kiene H, Helfand M, Altman DG, Sox H, Werthmann PG, Moher D, Rison RA, Shamseer L, Koch CA, Sun GH, Hanaway P, Sudak NL, Kaszkin-Bettag M, Carpenter JE and Gagnier JJ. CARE guidelines for case reports: explanation and elaboration document. *J Clin Epidemiol* 2017; 89: 218-235.