

**Surgical approach associated with cryotherapy of unicystic mandibular ameloblastoma  
with 19-year follow-up – a case report**

**Abordagem cirúrgica associada à crioterapia de ameloblastoma mandibular unicístico  
com seguimento de 19 anos – relato de caso**

**Abordaje quirúrgico asociado a la crioterapia del ameloblastoma mandibular  
unicístico con seguimiento de 19 años - reporte de caso**

Received: 10/03/2020 | Reviewed: 10/06/2020 | Accept: 10/10/2020 | Published: 10/11/2020

**Gabriel Sousa Lima**

ORCID: <https://orcid.org/0000-0002-7065-0493>

Universidade Federal de Uberlândia, Brasil

E-mail: [gabriel-sousa1@hotmail.com](mailto:gabriel-sousa1@hotmail.com)

**Cristóvão Marcondes de Castro Rodrigues**

ORCID: <https://orcid.org/0000-0002-0590-9075>

Hospital de Clínicas de Uberlândia, Brasil

E-mail: [crisovao-marcondes@hotmail.com](mailto:crisovao-marcondes@hotmail.com)

**Izabella Sol**

ORCID: <https://orcid.org/0000-0003-2384-9819>

Hospital de Clínicas de Uberlândia, Brasil

E-mail: [izabella.sol@hotmail.com](mailto:izabella.sol@hotmail.com)

**Vinícius Lima de Almeida**

ORCID: <https://orcid.org/0000-0002-2135-1040>

Hospital de Clínicas de Uberlândia, Brasil

E-mail: [viniciusl.dealmeida91@gmail.com](mailto:viniciusl.dealmeida91@gmail.com)

**Ricardo Pedro da Silva**

ORCID: <https://orcid.org/0000-0003-4505-2640>

Hospital de Clínicas de Uberlândia, Brasil

E-mail: [ricardopedro315@gmail.com](mailto:ricardopedro315@gmail.com)

**DanyellaCarolyna Soares dos Reis**

ORCID: <https://orcid.org/0000-0002-8548-0538>

Universidade Federal de Uberlândia, Brasil

E-mail: [danyellacsoaresr@gmail.com](mailto:danyellacsoaresr@gmail.com)

**Darceny Zanetta Barbosa**

ORCID: <https://orcid.org/0000-0002-8755-0931>

Universidade Federal de Uberlândia, Brasil

E-mail: [darcenyzanetta@ufu.br](mailto:darcenyzanetta@ufu.br)

**Flaviana Soares Rocha**

ORCID: <https://orcid.org/0000-0002-6759-2229>

Universidade Nacional de Brasília, Brasil

E-mail: [flavianasoares.rocha@gmail.com](mailto:flavianasoares.rocha@gmail.com)

**Cláudia Jordão Silva**

ORCID: <https://orcid.org/0000-0002-7114-4859>

Universidade Federal de Uberlândia, Brasil

E-mail: [cjordao1@gmail.com](mailto:cjordao1@gmail.com)

**Abstract**

Ameloblastoma is a benign odontogenic tumor of epithelial origin with slow, asymptomatic, rare growth and is associated with a high rate of recurrence, being responsible for 1% of mandibular tumors. There are several variations of these tumors, with solid / multicystic and unicystic types being the most recurrent. The signs are discrete and rarely noticed by the patient in the early stages. In the imaging examination, it presents itself as a well-delimited radiolucent image, which may be associated with the crown of an unerupted tooth, resorption of adjacent roots and vestibular-lingual medullary expansion. In the literature, the most appropriate treatment for the management of such pathology is still controversial, since there are conservative philosophies such as curettage, marsupialization (decompression) and defending currents of the radical surgical approach through resection with a safety margin. This study aims to report a case of curettage of follicular unicystic ameloblastoma with a single incidence of recurrence and treated again by means of a conservative surgical approach and continuing with a 19-year clinical preservation, without any clinical or imaging signs of recurrence.

**Keywords:** Ameloblastoma; Mandible; Surgical decompression; Curettage; Conservative treatment.

**Resumo**

O ameloblastoma é um tumor odontogênico benigno de origem epitelial com crescimento lento, assintomático, raro e está associado a alto índice de recorrência, sendo responsável por

1% dos tumores mandibulares. Existem várias variações desses tumores, sendo os tipos sólido / multicístico e unicístico os mais recorrentes. Os sinais são discretos e raramente percebidos pelo paciente nos estágios iniciais. No exame de imagem, apresenta-se como uma imagem radiolúcida bem delimitada, que pode estar associada à coroa de um dente não irrompido, reabsorção de raízes adjacentes e expansão medular vestibulo-lingual. Na literatura, o tratamento mais adequado para o manejo dessa patologia ainda é controverso, visto que existem filosofias conservadoras como a curetagem, a marsupialização (descompressão) e as correntes de defesa da abordagem cirúrgica radical por ressecção com margem de segurança. O objetivo deste trabalho é relatar um caso de curetagem de ameloblastoma folicular unicístico com incidência única de recidiva e tratado novamente por meio de abordagem cirúrgica conservadora e continuando com preservação clínica de 19 anos, sem quaisquer sinais clínicos ou de imagem de recidiva.

**Palavras-chave:** Ameloblastoma; Mandíbula; Descompressão cirúrgica; Curetagem; Tratamento conservador.

### **Resumen**

El ameloblastoma es un tumor odontogénico benigno de origen epitelial de crecimiento lento, asintomático, raro y se asocia a una alta tasa de recidiva, siendo responsable del 1% de los tumores mandibulares. Hay varias variaciones de estos tumores, siendo los tipos sólido / multiquístico y uniuístico los más recurrentes. Los signos son discretos y el paciente rara vez los nota en las primeras etapas. En el examen de imagen se presenta como una imagen radiolúcida bien delimitada, que puede estar asociada a la corona de un diente no erupcionado, reabsorción de raíces adyacentes y expansión medular vestibular-lingual. En la literatura, el tratamiento más adecuado para el manejo de dicha patología sigue siendo controvertido, ya que existen filosofías conservadoras como el curetaje, marsupialización (descompresión) y corrientes de defensa del abordaje quirúrgico radical mediante resección con margen de seguridad. Este estudio tiene como objetivo reportar un caso de legrado de ameloblastoma folicular uniuístico con una sola incidencia de recidiva y tratado nuevamente mediante abordaje quirúrgico conservador y continuando con una preservación clínica de 19 años, sin ningún signo clínico o imagenológico de recurrencia.

**Palabras clave:** Ameloblastoma; Mandíbula; Descompresión quirúrgica; Legrado; Tratamiento conservador.

## 1. Introduction

Ameloblastoma is a neoplasm of epithelial origin which, although rare, is reported as the second most common type of odontogenic tumors (Chae, Smoll, Hunter-Smith, & Rozen, 2015; McClary, et al., 2016). It is responsible for 1% of all jaw tumors and 11% of odontogenic tumors (Vallicioni et al., 2007). There is a prevalence between the fourth and fifth decade of life. While being rare in children and the elderly, with no predilection for sex or race, its trigger unknown (Thambi, Subitha, Mohan, & Letha, 2012; Menezes et al., 2017).

Although ameloblastoma is a slow-growing benign tumor and generally asymptomatic, it is aggressive and expands locally into other anatomical structures. The anatomical site, usually affected by the tumor, is in the posterior region of the mandible (França, Curioni, Paiva, & Vianna, 2012) and in retrospective clinical studies, the incidence of ameloblastomas in the maxilla was exceptionally low. The incidence rates of ameloblastomas vary from 1: 8.8 to 1:58 in the maxilla and mandible, respectively (Osterne, Brito, Alves, Cavalcante, & Souza, 2011; Selvamani, Yamunadevi, Basandi, & Madhushankari, 2014). Radiographically, the ameloblastoma presents as cystic, unilocular or multilocular lesions, being commonly associated with a include tooth, causing root resorption in adjacent units and simultaneously bone cortical expansion and/or perforation (Kim, Nam, & Yoon, 2017; Laborde, Nicot, Wojcik, Ferri, & Raoul, 2017).

The most recent classification of the World Health Organization (2017) distinguishes the more frequent and aggressive conventional ameloblastoma from its variants, peripheral ameloblastoma situated in soft tissues and unicystic ameloblastoma (El-Naggar, Chan, Grandis, Takat, & Slootweg, 2017).

The forms of treatment have been controversial and ranging from conservative to radical. Conservative approach (marsupialization and enucleation with curettage associated or not with auxiliary methods such as Carnoy's solution or cryotherapy) preserves the integrity of the bone and allows the continuous growth of the mandible, while radical treatment can cause aesthetic and functional sequelae, requiring surgical reconstruction (França et al., 2012; Hsu, Chiang, & Chen, 2014).

The objective of this article is to report a case of unicystic ameloblastoma in the posterior region of the mandible, submitted to a conservative surgical approach with a history of a single recurrence where the patient was reopened by conservative surgical therapy, through the curettage of the lesion. The following a 19-year clinical follow-up, without any indication of injury recurrence.

## **2. Methodology**

This article consists of an analytical and descriptive case study. This is a case of relevance to the dental field since the pathology described is evidenced in the literature, a hand with a follow-up as extensive as this one. An extensive literature review from 2000 to 2019 was carried out by searching the following electronic databases: PubMed, SciELO, Latin American and Caribbean Health Sciences (LILACS), showing that the incidence of accompaniment for similar cases was not as extensive as this.

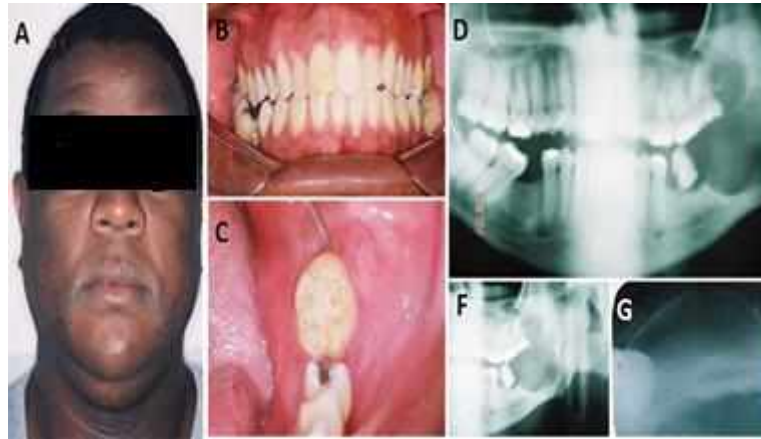
The work in question was not submitted to the ethics and research committee, as it is a case report for which the procedure to be performed was not experimental. The patient has the signature of two terms: free and clear concentration term on the surgical procedures performed throughout the treatment and concentration term regarding the use of images

### **2.1 Case Report**

Male patient, 35 years old, black, sought the area of Stomatology and Diagnosis of the Federal University of Uberlandia, State of Minas Gerais, on 04/04/2002 complaining about a volumetric increase on the left side of the face and painful symptomatology on the left mandibular molar (tooth 19).

During the anamnesis the patient denied any systemic alterations. Clinical examination revealed left facial asymmetry (Figure 1A), swelling in a region of the mandibular ramus with evident cortical bone expansion, associated with tooth 19 (Figure 1B and 1C).

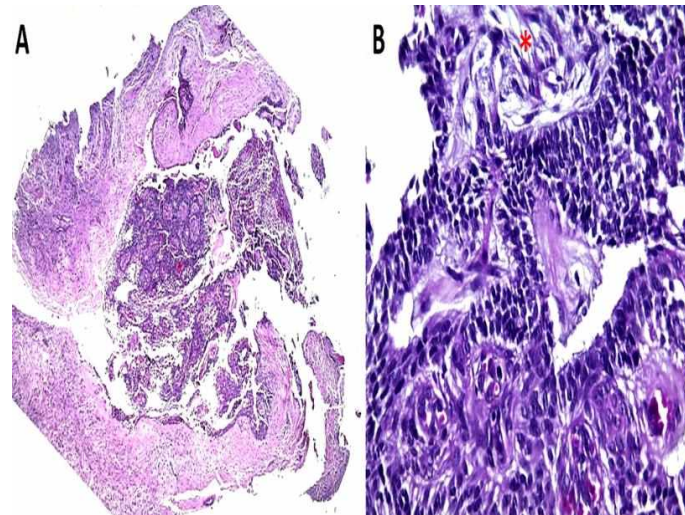
**Figure 1** - Extra oral aspect, note facial asymmetry with volumetric increase on the left side (A), Intraoral aspect (B), swelling in the region of mandibular angle associated with element 19 (C); Panoramic radiography (D); Enlargement of the panoramic radiography showing the lesion region (E); Occlusal radiography contacting the expansion of bone cortical(F).



Source: Authors.

The panoramic radiographic examination showed a radiolucency unilocular lesion with well-defined edges in parts of the body, angle and left mandibular ramus, associated with the crown of the dental element 19 with large root resorption (Figures 1D and 1E) and the occlusal radiograph confirmed bone cortical expansion (Figure 1F). Incisional biopsy of the lesion was performed and the result of histopathological analysis was conclusive for Ameloblastoma (Figure 2A-B).

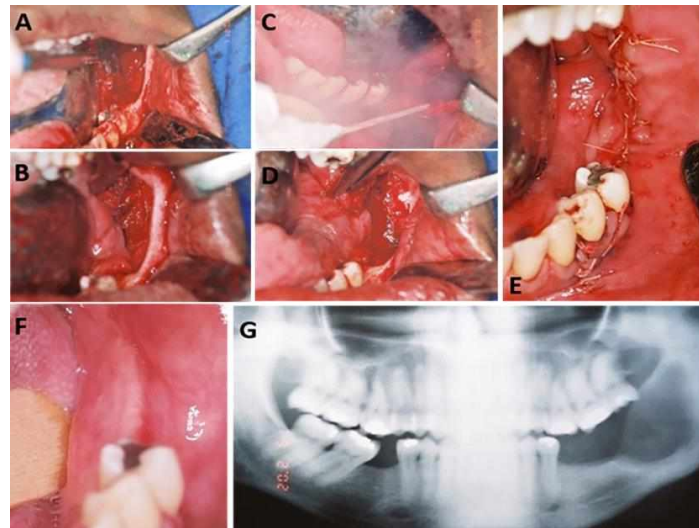
**Figure 2** - Histological image of the lesion: 4X increase (A) and 40X increase (B). Histopathological appearance revealing epithelial proliferation with ameloblastic aspect cells around the mesenchymal tissue and light-colored cytoplasm cells and ovoid or elongated nucleus in the internal portions mimicking the stellate reticulum of the enamel organ (\*).



Source: Authors

After the diagnosis, the surgical procedure was performed under general anesthesia and consisted of enucleation of the lesion, followed by cryotherapy in the lesion with application of refrigerant gas in the surgical field (Figure 3A-F). The material was collected for histopathological analysis and the result was conclusive for ameloblastoma predominantly follicular. The patient was kept in outpatient follow-up, presenting a good healing of mucosa and bone formation in the region of the lesion, however presented paresthesia in the left lower lip (Figure 3G and 2H). Monthly returns were maintained.

**Figure 3** - Exposure of the lesion (A); Enucleation of the lesion (B); Application of refrigerant gas, cryotherapy (C); Aspect of the surgical site after cryotherapy (D); Final suture (E), Aspect of the soft tissue of the region within 30 days postoperatively (F); Panoramic radiography of follow-up 2 months postoperatively (G).

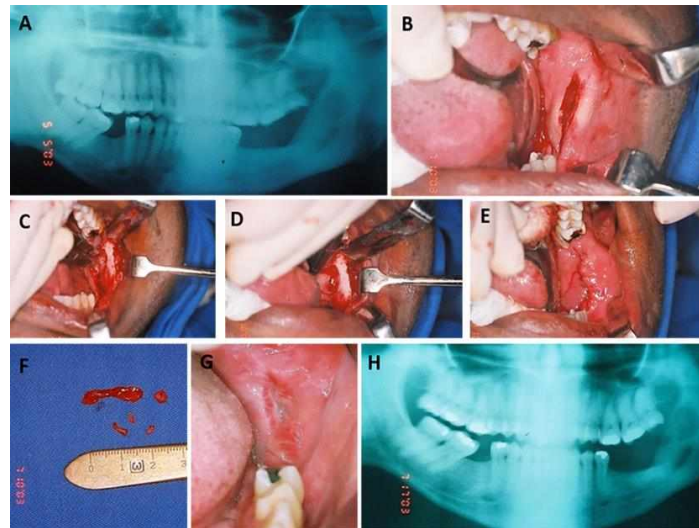


Fonte: Arquivo dos autores.

The patient was followed up on a monthly outpatient and in the 10th month reported episodes of pain in the left mandibular body region and viscous and stinking saliva. The intraoral examination showed a normal aspect of the mucosa. The radiographic evaluation showed the presence of a well-defined radiolucent area, approximately 2 cm in diameter (Figure 4A). The patient was oriented to use 0.12% chlorhexidine digluconate twice a day for seven days, and return in 10 days for reassessment. After reevaluation, the patient was again submitted to surgical procedure under general anesthesia for surgical inspection and removal of recurrent lesion and using cryotherapy in the surgical field (Figure 4). The patient evolved with good tissue healing and persistent paresthesia of the lower lip on the left side. Returns were maintained quarterly.



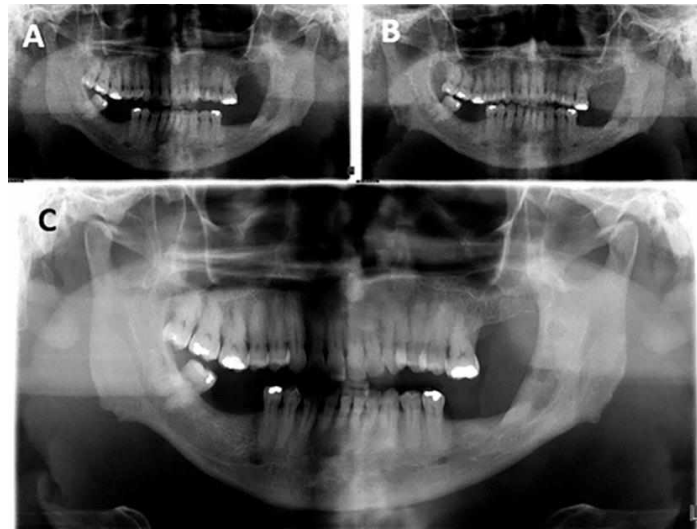
**Figure 4** - Panoramic radiography 10 months postoperatively, with image suggestive of recurrence (A); Incision (B); Enucleation of the lesion (C); Surgical area after enucleation and curettage of the lesion (D); Final suture (E); aspect of the enucleated lesion (F); Tissue healing (G); Panoramic radiography 1 week postoperatively of the second intervention (H).



Fonte: Arquivo dos autores.

Patient remained in quarterly returns and in 2018 complained of discomfort in the left mandibular angle region. The radiographic examination revealed a circumscribed radiolucent image in the left mandibular ramus region (Figure-5A). Under the circumstances, the patient underwent exploratory surgery under local anesthesia to investigate possible further recurrence. The collected material was sent for histopathological analysis and the result was conclusive of bone tissue without pathological signs. The patient is still under semi-annual follow-up with no clinical or radiographic signs of recurrences so far (Figure 5).

**Figure 5** - Accompanying panoramic radiographs, May/19 (A); January/20 (B) and September/2020 (C).



Fonte: Arquivo dos autores.

### 3. Discussion

Ameloblastomas are slow-growing, painless, benign but very aggressive and locally invasive tumors. It is more frequent in the second decade of life, with no predilection for sex or ethnicity (Osterne et al., 2011; Thambi et al., 2012; Chae et al., 2015). The origin of ameloblastoma refers to the embryogenic development of the teeth, and it is currently accepted that the epithelium of the dental lamina is the primary tissue for its formation (Moraes et al., 2014).

The diagnosis for this lesion cannot be predicted before microscopic examination of the lesion since there are several histological variants, such as follicular, plexiform, unicystic and desmoplastic (Kumar, 2014). The differential diagnosis of unicystic ameloblastoma is usually associated with dentiger cyst or odontogenic keratocyst (Park, Canção, Seo, Lee, & Kim, 2014).

The therapeutic approach of unicystic ameloblastoma is based on the histological pattern of the lesion (Hsu et al., 2014; Wright & Vered, 2017). When these epithelial cells are limited to the cystic lining, we have a luminal histological pattern. However, the invasion of the cystic lumen by the epithelium configures an intraluminal pattern. When the connective capsule is compromised by the presence of tumor epithelium, it is called a mural pattern. The luminal and intraluminal patterns are associated with lower rates of recurrence, so they are eligible for conservative therapy (Chouinard, Peacock, Faquin, & Kaban, 2017). Otherwise,

the mural pattern presupposes tumor invasion in adjacent tissues, and the treatment of choice is resection with safety margins of 1-1.5cm (Kim et al., 2017). The treatment option for unicystic ameloblastomas follows conservative therapy (marsupialization/enucleation), especially when dealing with younger patient, offering lower morbidity and consequently better quality of life to the patient ((Hsu et al., 2014; Kim et al., 2017). In the report described, by histological analysis the lesion did not present aggressive characteristics that forced the medical team to adopt more radical treatment, such as mandibular resection. The curettage and the cryotherapy were suitable for this case considering all the good points.

The technique of cryotherapy or application of Carnoy's solution aims to reduce the chances of maintaining active tumor cells within the bone remnant, through the physical cooling action of cryotherapy or the chemical action of the Carnoy's solution in the surgical field in an area of 2-3mm depth (Kruschewsky, Cincurá, Teixeira, & Filho, 2010). The adoption of cryotherapy proved to be easy to apply and efficient, as presented.

The choice of appropriate treatment should be based on the size and location of the lesion, the possibility of recurrence, and radiographic evaluation if there is cortical bone perforation. The literature suggests aggressive surgical treatments, such as resection with or without reconstruction. However, radical treatment can cause facial deformities and have psychological consequences to the patient, especially in young patients (Kumar, 2015). As presented in the case, the level of deformity that would be caused to the patient if the radical approach had been chosen, would be very high, but the age and the limitations of rehabilitation were discussed and the most conservative surgical approach was chosen.

Conservative interventions are generally preferred for unicystic ameloblastomas in the mandible. But are not suggested when they affect the maxilla, even with very rare incidences in this region, because of the cancellous bone architecture of the maxilla that facilitates the dissemination of the tumor and proximity to the orbit, pterygomaxillary fossa and skull (Isacsson, Andersson, Forsslund, Bodin, & Thomsson, 1986; Li, Wu, Yu, & Yu, 2000). The case presented here shows that the curettage of the ameloblastoma has been effective, considering the number of recurrences presented and the time of follow-up that the patient presents.

Regarding unicystic ameloblastomas, the recurrence rate is reported in 7 and 20% of the cases submitted to conservative therapy; therefore, rigorous and long-term follow-up is extremely important for treatment success, since more than 65% of recurrences occur within the first five years of surgery; and postoperative imaging exams routinely performed favor the early detection of recurrence, to perform surgical reintervention (Lee, Samman, & Ng, 2004;

Anavi, Gal, Miron, Calderon, & Allon, 2011; Hsu et al., 2014; Selvamani et al., 2014). As in the report presented, the recurrence was present in the first year of the surgical approach after diagnosis, however due to the levels of sequel left by the adoption of radical treatments, the surgical team opted for another attempt of a conservative surgery through the curettage of the lesion; showing to be a good option for treatments, since the case continues with long follow-up, without any signs of recurrence of the lesion, maintaining the anatomical structure of the patient, avoiding the results from resection surgeries.

#### **4. Final Considerations**

The unicystic ameloblastomas, despite being benign lesions of silent course initially, being discovered in routine radiographic examinations, present a risk of late growth associated with functional and aesthetic disorders and impairment of noble structures. Conservative treatment plays an important role in the management of unicystic ameloblastoma as it has a lower recurrence rate when compared to multicystic and peripheral ameloblastoma. The macroscopic type, histological, age and medical history of the patient are the main determinants for choosing the appropriate therapy. Radical treatment through resection with safety margin is considered in the mural variant, given its infiltrative characteristics to adjacent tissues.

The detailed and long-term follow-up for at least five years is of fundamental importance, since higher incidences of recurrence occur in this interval.

It would be of great value for literature and for the maxillofacial surgery class, to have more publications of treatments considered as conservative and with an extensive follow-up, since because it is a highly recurrent pathology, it is essential to show that the adoption of conservative treatments is still of great importance as a method of choice, considering the minimum levels of morbidities that they cause

#### **References**

Anavi, Y., Gal, G., Miron, H., Calderon, S., & Allon, D. M. (2011). Decompression of odontogenic cystic lesions: clinical long-term study of 73 cases. *Oral Surgery, Oral Medicine, Oral Pathology, Oral Radiology and Endodontics*, 112(2), 164-169.

Chae, M. P., Smoll, N. R., Hunter-Smith, D. J., & Rozen, W. M. (2015). Establishing the natural history and growth rate of ameloblastoma with implications for management: systematic review and meta-analysis. *PLoS One*, 10(2), e0117241.

Chouinard, A. F., Peacock, Z. S., Faquin, W. C., & Kaban, L.B. (2017). Unicystic Ameloblastoma Revisited: Comparison of Massachusetts General Hospital Outcomes With Original Robinson and Martinez Report. *Journal of Oral and Maxillofacial Surgery*, 75(11), 2369-2378.

El-Naggar, A. K., Chan, K. C. J., Grandis, J. R., Takat, T., & Slootweg, P. J. (2017). *World Health Organization Classification of Head and Neck Tumours*. (4th ed.), Lyon: IARC.

França, L. J., Curioni, A. O., Paiva, D. L., & Vianna, D. M. (2012). Ameloblastoma demographic, clinical and treatment study - analysis of 40 cases. *Brazilian Journal of Otorhinolaryngology*, 78(3), 38–41.

Hsu, M. H., Chiang, M. L., & Chen, J. K. (2014). Unicystic ameloblastoma. *Journal of Dental Sciences*, 9,407-411.

Isacsson, G., Andersson, L., Forsslund, H., Bodin, I., & Thomsson, M. (1986). Diagnosis and treatment of the unicystic ameloblastoma. *International Journal of Oral and Maxillofacial Surgery*, 15(6), 759-764.

Kim, J., Nam, E., & Yoon, S. (2017). Conservative management (marsupialization) of unicystic ameloblastoma: literature review and a case report. *Maxillofacial Plastic and Reconstructive Surgery*, 39(1), 38.

Kruschewsky, L. S., Cincurá, C., Teixeira, F. A., & Filho, F. V. M. (2010). Ameloblastoma: aspectos clínicos e terapêuticos. Ameloblastoma: clinical and therapeutics aspects. *Revista Brasileira de Cirurgia Craniomaxilofacial*, 13(4), 241-245.

Kumar, B. S. (2014). Unicystic ameloblastoma of the mandible – report of two cases with review of literature. *Journal of Clinical and Diagnostic Research*, 8(5), 7-9.

Kumar, V. (2015). Conservative surgical approach to aggressive benign odontogenic neoplasm: a report of three cases. *Journal of the Korean Association of Oral and Maxillofacial Surgery*, 41(1), 37-42.

Laborde, A., Nicot, R., Wojcik, T., Ferri, J., & Raoul, G. (2017). Ameloblastoma of the jaws: Management and recurrence rate. *European Annals of Otorhinolaryngology, Head and Neck Diseases*, 134(1), 7-11.

Lee, P. K., Samman, N., & Ng, I. O. (2004). Unicystic ameloblastoma use of Carnoy's solution after enucleation. *International Journal of Oral and Maxillofacial Surgery*, 33(3), 263-267.

Li, T. J., Wu, Y. T., Yu, S. F., & Yu, G. Y. (2000). Unicystic ameloblastoma: a clinicopathologic study of 33 Chinese patients. *The American Journal of Surgical Pathology*, 24(10), 1385-1392.

McClary, A. C., West, R. B., McClary, A. C., Pollack, J. R., Fischbein, N. J., Holsinger, C. F., Sunwoo, J., Colevas, A. D., & Sirjani, D. (2016). Ameloblastoma: a clinical review and trends in management. *European Archives of Oto-Rhino-laryngology*, 273(7), 1649-1661.

Menezes, L. M., Cruz, E. L. S., Junior, J. T. C., Kataoka, M. S. S., Junior, S. M. A., & Pineiro, J. J. V. (2017). Maxillary ameloblastoma in an elderly patient: Report of a surgical approach. *Human Pathology: Case Reports*, 10, 25–29.

Moraes, F. B., Cardoso, R. M. N., Rodrigues, S. V., Dutra, M.V. F., Pereira, U. R., & Borges, T. R. S. A. (2014). Ameloblastoma: a clinical and therapeutic analysis on six cases. *Revista Brasileira de Ortopedia*, 49(3), 305-308.

Osterne, R. L., Brito, R. G., Alves, A. P., Cavalcante, R. B., & Souza, F. B. (2011). Odontogenic tumors: a 5 years retrospective study in a Brazilian population and analysis of 3406 cases reported in literature. *Oral Surgery, Oral Medicine, Oral Pathology, Oral Radiology and Endodontics*, 111(4), 474-481.

Park, H. S., Canção, I. S., Seo, B. M., Lee, J. H., & Kim, M. J. (2014). A eficácia da descompressão em pacientes com cistos dentígeros, tumores odontogênicos queratocísticos e ameloblastoma unicístico. *Journal of the Korean Association of Oral and Maxillofacial Surgery*, 40(6), 260–265.

Selvamani, M., Yamunadevi, A., Basandi, P., & Madhushankari, G. (2014). Analysis of prevalence and clinical features of multicystic ameloblastoma and its histological subtypes in South Indian sample population: a retrospective study over 13 years. *Journal of Pharmacy & Bioallied Sciences*, 6(Suppl 1), S131-4.

Thambi, R., Subitha, K., Mohan, S., & Letha, V. (2012). Preoperative cytological diagnosis of ameloblastoma involving the maxilla. *Indian Journal of Pathology & Microbiology*, 55(4), 591-592.

Vallicioni, J., Loum, B., Dassonville, O., Poissonnet, G., Ettore, F., & Demard F. (2007). Ameloblastomas. *Annales d'Oto-laryngologie et de Chirurgie Cervico faciale*, 124(4), 166-171.

Wright, J. M., & Vered, M. (2017). Update from the 4th Edition of the World Health Organization Classification of Head and Neck Tumours: Odontogenic and Maxillofacial Bone Tumors. *Head and Neck Pathology*, 11(1), 68-77.

#### **Percentage of contribution of each author in the manuscript**

Gabriel Sousa Lima – 30%

Cristóvão Marcondes de Castro Rodrigues – 10%

Izabella Sol – 10%

Vinícius Lima de Almeida – 10%

Ricardo Pedro da Silva – 5%

Danyella Carolyn Soares dos Reis – 5%

Darceny Zanetta Barbosa – 5%

Flaviana Soares Rocha – 5%

Cláudia Jordão Silva – 20%