



UNIVERSIDADE FEDERAL DE UBERLÂNDIA
PROGRAMA DE RESIDÊNCIA UNIPROFISSIONAL EM CIRURGIA E
TRAUMATOLOGIA BUCOMAXILOFACIAL

REMOVAL OF FIREARM PROJECTILE FROM THE
MAXILLARY SINUS: A CASE REPORT

Uberlândia-MG
2021

Cristóvão Marcondes de Castro Rodrigues

**REMOVAL OF FIREARM PROJECTILE FROM THE
MAXILLARY SINUS: A CASE REPORT**

Trabalho de Conclusão de Residência apresentado como trabalho final da pós-graduação *latu-senso* na Universidade Federal de Uberlândia, como parte dos requisitos exigidos para a obtenção do título de Especialista em Cirurgia e Traumatologia Bucomaxilofacial.

Orientador: Prof. Dr. Jonas Dantas Batista

Uberlândia-MG

2021



UNIVERSIDADE FEDERAL DE UBERLÂNDIA
 Coordenação do Programa de Residência Multiprofissional
 Avenida Pará, 1720, Bloco 2U, Sala 23 - Bairro Urusuarana, Uberlândia-MG, CEP 38400-902
 Telefone: 34 3225-8604 - coorpmu@famed.ufu.br



ATA DE DEFESA - PÓS-GRADUAÇÃO

Às 14 horas do dia 21 de janeiro de 2021, online por vídeo conferência, reuniu-se em sessão pública, a Banca Examinadora de defesa do Trabalho de Conclusão de Residência TCR: "REMOVAL OF FIREARM PROJECTILE FROM THE MAXILLARY SINUS: A CASE REPORT", de autoria do(a) residente Cristóvão Marcondes de Castro Rodrigues. A Banca Examinadora é composta por: Orientador(a) e presidente da banca: Prof. Dr. Jonas Dantas Batista, cirurgião dentista - FO/UFU; membros titulares: Profa. Dra. Cláudia Jordão Silva, cirurgiã dentista - FO/UFU; Prof. Dr. Marcelo Caetano Parreira da Silva, cirurgião dentista - FO/UFU e suplente Profa. Dra. Flaviana Soares Rocha, cirurgiã dentista - FO/UnB. Iniciando os trabalhos o(a) presidente, concedeu a palavra ao(a) residente por 15 minutos, para exposição de seu trabalho, tendo 5 minutos de acréscimo. A seguir, o(a) presidente concedeu a palavra, pela ordem sucessivamente, aos (às) examinadores(as), que passaram a arguir o(a) residente por, no máximo, 10 minutos cada, tendo sido assegurado a eles igual tempo para resposta. Terminada a arguição que se desenvolveu dentro dos termos regulamentais, a Banca, em sessão secreta, atribuiu o resultado, considerando o(a) residente:

APROVADO.

Com as seguintes recomendações: Observar correções sugeridas pela Banca Examinadora.

Esta defesa faz parte dos requisitos necessários à obtenção do título de Especialista.

Nada mais havendo a tratar foram encerrados os trabalhos. Foi lavrada a presente ata que após lida e achada conforme foi assinada pela Banca Examinadora.



Documento assinado eletronicamente por Cláudia Jordão Silva, Professor(a) do Magistério Superior, em 21/01/2021, às 18:23, conforme horário oficial de Brasília, com fundamento no art. 6º, § 1º, do [Decreto nº 8.539, de 8 de outubro de 2015](#).



Documento assinado eletronicamente por Marcelo Caetano Parreira da Silva, Professor(a) do Magistério Superior, em 23/01/2021, às 13:15, conforme horário oficial de Brasília, com fundamento no art. 6º, § 1º, do [Decreto nº 8.539, de 8 de outubro de 2015](#).



Documento assinado eletronicamente por Jonas Dantas Batista, Professor(a) do Magistério Superior, em 23/01/2021, às 13:44, conforme horário oficial de Brasília, com fundamento no art. 6º, § 1º, do [Decreto nº 8.539, de 8 de outubro de 2015](#).



A autenticidade deste documento pode ser conferida no site https://www.sei.ufu.br/sei/controlador_externo.php?acao=documento_conferir&id_orgao_acesso_externo=0, informando o código verificador 2490705 e o código CRC 7D54EBF1.

Sumário

Resumo/Abstract-----	5
Introduction-----	6
Case Report-----	7
Discussion-----	9
Concluson-----	11
References-----	12
Figure legends-----	14
Figures-----	15
Attachments-----	18
Published article-----	20

Resumo

Corpos estranhos nos seios paranasais são ocorrências raras que têm sido esporadicamente relatadas na literatura em todo o mundo. Projéteis de arma de fogo, punhais, facas, fragmentos de vidro, pedras, dentes e madeira podem ficar alojados nos tecidos moles e duros do rosto. O manejo e o prognóstico nesses casos dependem da composição e localização do corpo estranho, bem como da presença ou ausência de infecção. Embora haja relatos envolvendo os tecidos moles da face, os seios etmoidal, esfenoidal, frontal e maxilar são os locais mais frequentemente envolvidos. A principal manifestação dessa condição é sinusite decorrente de infecção e / ou inflamação causada pelo corpo estranho, que é um objeto contaminado. Relatamos um caso de remoção de um projétil de arma de fogo localizado no seio maxilar de um paciente de 34 anos de idade, sob anestesia local.

Palavras-Chave: Seio maxilar. Sinusite maxilar. Cirurgia bucal. Ferimentos por arma de fogo

Abstract

Foreign bodies in the paranasal sinuses are rare occurrences that have sporadically been reported in the literature worldwide. Firearm projectiles, daggers, knives, glass fragments, stones, teeth, and wood can get lodged in the soft and hard tissues of the face. The management and prognosis in such cases depend on the composition and location of the foreign body as well as on the presence or absence of infection. Although there are reports involving the soft tissues of the face, the ethmoid, sphenoid, frontal, and maxillary sinuses are the most frequently involved sites. The main manifestation of this condition is sinusitis arising from infection and/or inflammation caused by the foreign body, which is a contaminated object. We report a case of removal of a firearm projectile located in the maxillary sinus of a 34 year old patient under local anesthesia.

Indexing terms: Maxillary Sinus, Maxillary Sinusitis, Firearm Wounds, Oral Surgery

Introduction

The maxillary sinus is the largest of the paranasal sinuses and corresponds to a pneumatic space located bilateral inside the maxillary bone. Its lining is composed of pseudostratified ciliated columnar epithelium with mucus-producing cells (goblet cells) [1]. As an anatomical structure, the functions of the maxillary sinus include facial bone weight reduction, voice resonance enhancement, thermal insulation of sensitive structures such as dental roots and eyes, humidification and heating of the inhaled air, and immunological defense [2].

The presence of foreign bodies inside the paranasal sinuses is a rare occurrence, and the most frequent cause is automobile accidents, firearm assaults, psychiatric disorders, and iatrogenic injury during surgical procedures [3], [4]. Reports in the literature also describe the intrusion of anatomical structures into the maxillary sinus following facial trauma [2], [5]. The displacement of dental elements in cases of maxillary fracture and the dislocation of an eyeball into the sinus cavity in fractures of the orbital cavity have also been reported [5].

The development of chronic sinusitis as a consequence of these accidents is quite common; however, its diagnosis by clinical physicians, otolaryngologists, and general dentists is challenging due to failures in systematic examination and lack of request for complementary imaging exams [6]. The most suitable treatment for chronic sinusitis caused by a foreign body is the surgical removal of the body along with oral antibiotic therapy [3], [6].

In the present case report, we aim to describe the clinical case of a victim of a firearm injury in whom the projectile was lodged in the left maxillary sinus and was surgically removed.

Case Report

A 34-year-old melanoderm male patient was referred to the Hospital de Clínicas of the Federal University of Uberlândia. He was the victim of a firearm injury to the head. The patient was examined by the general surgery team for primary trauma assessment. He had a Glasgow score of 14 and denied loss of consciousness at the accident site. On clinical examination, there was a projectile entry hole in the parietal region, an exit hole was absent, and persistent epistaxis was present. For secondary evaluation of the patient, computed tomography (CT) imaging of the head and face (Figure 1A and B) was requested and the clinical opinion of the neurosurgery and oral and maxillofacial trauma surgery (CTBMF) teams was sought.

[Figure 1 here]

The management by the general surgery team involved tetanus vaccination and tetanus serum (5000 IU) was administered because the wound was deep and contaminated and because the patient's immunization status was unknown.

After evaluation of the CT images, the clinical management by the neurosurgery team was to pursue conservative treatment for the parietal bone fracture, perform wound debridement, undertake rigorous neurological surveillance, and obtain a second CT scan for control within 24 h.

The clinical examination performed by the CTBMF team did not show crepitation, depression, or mobility of the facial bones. The patient no longer experienced epistaxis. CT showed fracture of the left parietal bone, emphysema in the frontal region, right maxillary hamosinus, and the projectile lodged in the posterior region of the right maxillary sinus.

The patient was referred to the CTBMF outpatient clinic after discharge from the hospital for the removal of the projectile under local anesthesia. During anamnesis, the patient denied comorbidities and allergies, reported social alcohol consumption, and denied illicit drug use, and there was no contraindication for the procedure. Before the outpatient procedure, a Waters view X-ray (Figure 1C) and an anteroposterior skull X-ray (Figure 1D) were performed to examine if the projectile had been displaced.

Initially, the patient was medicated with the benzodiazepine midazolam (15 mg orally) and antibiotic prophylaxis with amoxicillin (1 g) 1 h preoperatively. Anesthetic blockade of the posterior, middle, and anterior alveolar nerves as well as of the right greater palatine nerve was performed using 4 tubes containing 2% lidocaine with vasoconstrictor epinephrine at a concentration of 1:100,000.

Caldwell–Luc surgical approach was planned, with an incision made in the bottom of the right maxillary vestibule extending from the canine to the first molar with mucoperiosteal flap detachment and exposure of the anterior wall of the maxillary sinus (Figure 2A). Guiding holes were drilled using a spherical drill #4 and joined under abundant irrigation for delimiting the surgical window to access the maxillary sinus (Figure 2B). After removal of the bone window and with direct access to the maxillary sinus, the projectile was located (Figure 2C) and removed using a Lucas curette (Figure 2D). Vigorous irrigation with 0.9% saline was performed. The bone fragment that was removed for access to the maxillary sinus

was repositioned at an angle in relation to the initial position and fixed with a 5-hole titanium plate of the 2.0 system using 4 5-mm monocortical screws (Figure 2E). The surgical bed was profusely re-washed with saline 0.9% and the wound was sutured using 4-0 Monocryl[®] thread (Figure 2F).

[Figure 2 here]

The patient was prescribed the following during discharge: amoxicillin (875 mg) + potassium clavulanate (125 mg), every 8 h for 7 days; dexamethasone (4 mg), every 24 h for 3 days, dipyrone sodium (500 mg), every 6 h for 3 days; collutorium with chlorhexidine (0.12%; 10 mL), every 8 h for 7 days; and oxymetazoline (0.025%), every 12 h for 10 days.

On the follow-up visit 7 days postoperatively, the patient did not report complaints and the appearance of the surgical wound was good. An anteroposterior radiography (Figure 3A) and Waters view radiography (Figure 3B) of the mandible were performed. No changes in the maxillary sinus were observed. At 30 days postoperatively, a face panoramic radiography was performed (Figure 3C) that did not show changes in the operated area, and the patient was discharged.

[Figure 3 here]

Discussion

Penetration of foreign bodies in the maxillofacial region is a rare event and there are few reports in the literature; approximately a third of such cases are not diagnosed during the first evaluation [6]. The most affected paranasal sinus is the maxillary sinus [7].

During clinical examination, the possibility of a foreign body should be considered when trauma with the presence of persistent inflammatory signs and difficulty in tissue healing are reported. The anamnesis should be thorough, seeking the kinetics and the trauma agent to understand the trajectory of the foreign body and thus investigating potential injury to important structures of the oral–maxillofacial complex [4], [6].

The presence of foreign bodies in the maxillary sinus may lead to surrounding bone resorption and infectious complications characterized by inflammation of the mucous membrane of this sinus [8]. Infection in facial tissues is common in cases of a foreign body such as a firearm projectile because these foreign bodies are typically not sterile and acts as a niche for various microorganisms; in such cases, antibiotic therapy should be adopted to minimize the risk of postoperative complications [15]. The most commonly used drugs in such cases are penicillins along with beta-lactam antibiotics, second-generation cephalosporins, or azalides [8], [15]. The use of these broad-spectrum antibiotics is appropriate because the projectile is not sterile, and as observed in the present case, the structure in which the object gets lodged is naturally colonized by microorganisms specific to the upper airway, such as *Streptococcus* spp., *Actinomyces* spp., *Fusobacterium* spp., and *Staphylococcus* spp. [1], [2]. In addition to the indicated antibiotic prophylaxis, tetanus prophylaxis should be concomitantly initiated.

The clinical presentation of the foreign body varies, which is a challenge to the surgeon both in terms of diagnosis and surgical procedure. Factors including object size, difficulty of access, and anatomical proximity of the foreign body to adjacent vital structures should be considered when selecting the most appropriate operative technique [9].

Imaging exams are important to aid in planning the removal of the foreign body from the facial structures. These include planar radiography, CT, magnetic resonance imaging (MRI), and ultrasonography (US), which can be used depending on the location and composition of the foreign body [10].

Conventional radiography is typically the first complementary examination requested due to its low cost, easy access, and usefulness in identifying the foreign body [6], [9]. However, in several cases, it is not possible to detect the foreign body via conventional radiographs and CT is required. Both are particularly important in the diagnosis of metallic foreign bodies. In cases wherein the foreign body is a wooden object, its density on CT may be similar to air, rendering it difficult to identify the object. Therefore, some researchers suggest performing MRI, which should be avoided when a foreign body of metallic origin is suspected because MRI may lead to the movement of the foreign body owing to the magnetic field. Therefore, knowledge regarding the kinetics and the agent causing the trauma is essential [10], [11].

Retention of firearm projectiles in the tissues can cause serious complications. The presence of the projectile in the tissues is an hindrance to the healing of the lesion because the

metals present in the projectile undergo electrochemical oxidation by body fluids, thereby leading to corrosion and causing infection [12]. In the present case, the decision to remove the projectile of the maxillary sinus was based on the elevated risk of progression to an infectious condition.

The Caldwell–Luc approach is often reported in the literature for the treatment of alterations in the maxillary sinus, particularly in the removal of foreign bodies, because it offers ample space for the procedure [13]. The technique consists of osteotomy of a part of the anterior wall of the maxillary sinus via which the foreign body is removed and curettage of the infected sinus mucosa. Despite the frequent reports in the literature of complications associated with the Caldwell–Luc procedure, including facial asymmetry, dacryocystitis, nerve injury, tooth devitalization, and oroantral fistula, the experts agree that these morbidities are also related to the surgeon’s experience [13]. The Caldwell–Luc approach was used in the present case and facilitated complete access to the site of the projectile and its removal. Moreover, there were no postoperative complications, which is consistent with the literature regarding the efficiency of this approach.

Endoscopic surgery emerges as an alternative to the Caldwell–Luc approach for maxillary sinus access. The technique provides adequate visualization of the surgical field, low morbidity, and high acceptance by the patient [14]. However, the lack of specialized professionals and insufficient logistical resources in public and private services render the routine use of this procedure impossible.

Conclusion

The presence of a foreign body should be investigated via a thorough clinical examination whenever there is a history of trauma in the oral–maxillofacial complex. Although the presence of a foreign body in the maxillary sinus is an infrequent event, it can cause local and systemic changes. Therefore, when a foreign body is detected, its removal should be performed at the earliest to avoid infectious complications and lesions to the adjacent anatomical structures. Surgical access by the Caldwell–Luc approach provides an adequate field for the removal of foreign bodies within the maxillary sinus.

References

1. Miloro M, Ghali GE, Larsen PE, Waite PD. Principles of Peterson's oral axillofacial surgery. 2th ed. São Paulo: Santos; 2009. v. 1. p. 295-297.
- 2- Freitas TMC, Farias JG, Mendonça RG, Alves MF, Ramos Jr. RP, Cândia AV. Oroantral fistulas: diagnosis and treatment proposals. Rev Bras Otorrinolaringol. 2003;69(6):838-44. <https://doi.org/10.1590/S0034-72992003000600018>.
- 3- Sverzut CE. Accidental displacement of impacted maxillary third molar: a case report. Braz Dent J. 2005;16(2):167-170. <https://doi.org/10.1590/S0103-64402005000200015>.
- 4- Peterson LJ, Ellis III E, Hupp JR, Tucker MR. Contemporary oral and maxillofacial surgery. 4th. Rio de Janeiro: Guanabara Koogan; 2005.
- 5- Tung TC. Dislocation of anatomic structures in to the maxillary sinus after craniofacial trauma. Plast Reconstr Surg. 1998;101(7):1904-1908. <https://doi.org/10.1097/00006534-199806000-00019>
- 6- Rebouças DS, Lima RRS, Junior WGPR, Assis AF, Zerbinati LPS. Chronic sinusitis due to foreign body in maxillary sinus-case report. Rev Bahiana Odontol. 2014;5(2):131-136.
- 7- Vale DS, Araujo MM, Cavalieri I, Santos MBP, Canellas JVS. Maxillary sinusitis of Dentistry Origin: Case report. Port J Stomatol Dent Med Maxillofacial Surg. 2010;51(2). [https://doi.org/10.1016/S1646-2890\(10\)70003-0](https://doi.org/10.1016/S1646-2890(10)70003-0).
- 8- Cavalcante WC, Coelho HA, Neto AIT, Santos LCS, Carvalho MC. Foreign Body in the Intimacy of the Bones of the Face: Case report. Braz J Oral Maxillofac Surg. 2010;10(1):97-102.
- 9- Morais HHA, Rocha NS, Gondim DGA, Melo AR. Foreign body in maxillary sinus: atypical case report. Rev Cir Traumatol Buco-Maxilo-Fac. 2007;7(1):65-70.
- 10- Casanova FHC, Mello Filho PAA, Nakanami DM, Manso PG. Intra-orbital organic foreign body: tomographic evaluation and conduct. Arq Bras Oftalmol. 2001; 64: 297-301. <https://doi.org/10.1590/S0004-27492001000400005>
- 11- Ohba T, Morimoto Y, Nagata Y, Tanaka T, Kito S. Comparison of the panoramic radiographic and CT features of post-Caldwell-Luc maxillary sinuses. Dento Maxillo Fac Radiol. 2000;29:280-285. <https://doi.org/10.1038/sj/dmfr/4600544>
- 12- McQuirter JL, Rothenberg SJ, Dinkins GA, Manalo M, Kondrashov V, Todd AC. The effects of retained lead bullets on body lead burden. J Trauma. 2001;50:892-899. <https://doi.org/10.1097/00005373-200105000-00020>

- 13- Soares DO. Long-term traumatic foreign body in maxillary sinus. *Scientific Journal of the Cema Institute of Ophthalmology and Otorhinolaryngology*. 2005;7(7):20-21.
- 14- Lima MM, Moreira CA, Silva VC, Freitas MR. 34 Self-inflicted foreign bodies in the maxillary sinus. *Braz J Otorhinolaryngol*. 2008;74(6):948. [https://doi.org/10.1016/S1808-8694\(15\)30162-2](https://doi.org/10.1016/S1808-8694(15)30162-2).

Figure legends

Figure 1: (A) Helical tomography (axial view) showing the projectile lodged in the posterior wall of the right maxillary sinus with the presence of sinus hemosinus ; (B) Helical tomography (sagittal view) showing the projectile in the posterior wall of the right maxillary sinus; (C) Waters view radiograph of the face 30 days after trauma showing displacement of the projectile to the floor of the right maxillary sinus; (D) Anteroposterior radiograph of the skull showing the projectile on the floor of the maxillary sinus.

Figure 2: (A) Fracture of the anterior wall of the right maxillary sinus; (B) Osteotomy of the anterior wall of the right maxillary sinus using the fracture line for easy access; (C) Projectile on the floor of the maxillary sinus ; (D) Maxillary sinus after projectile removal; (E) Plate System 2.0 and 5-mm screws stabilizing the fragment of the bone window; (F) Suturing at the proper position using Monocryl 4.0.

Figure 3: (A) Anteroposterior radiograph of skull (face) showing the positioned plate and radiolucent right maxillary sinus; (B) Waters view radiograph of the face at day 30 postoperatively; (C) Panoramic radiograph showing the positioning of the plate and radiolucent maxillary sinus.

Figure-1

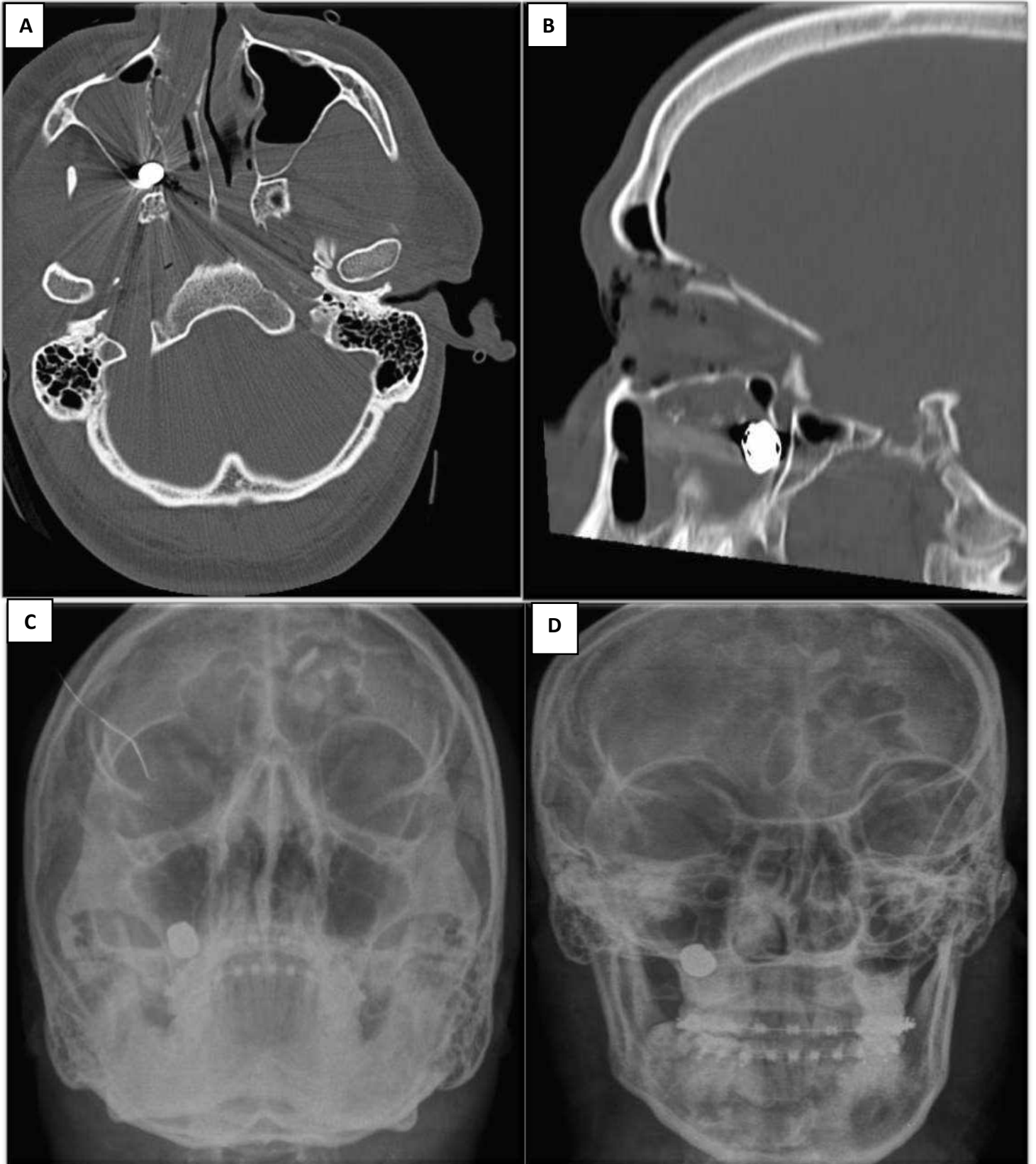


Figure-2

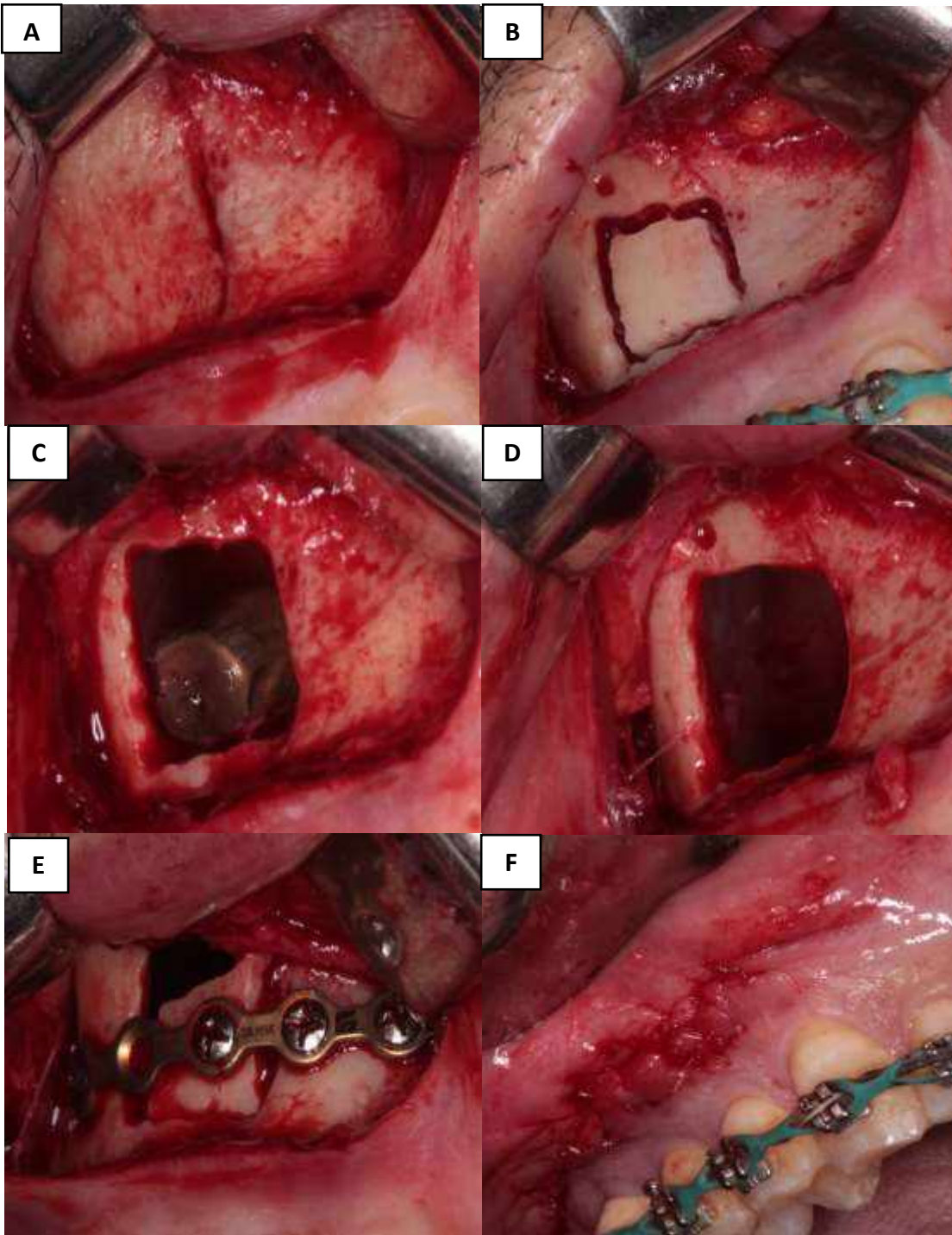
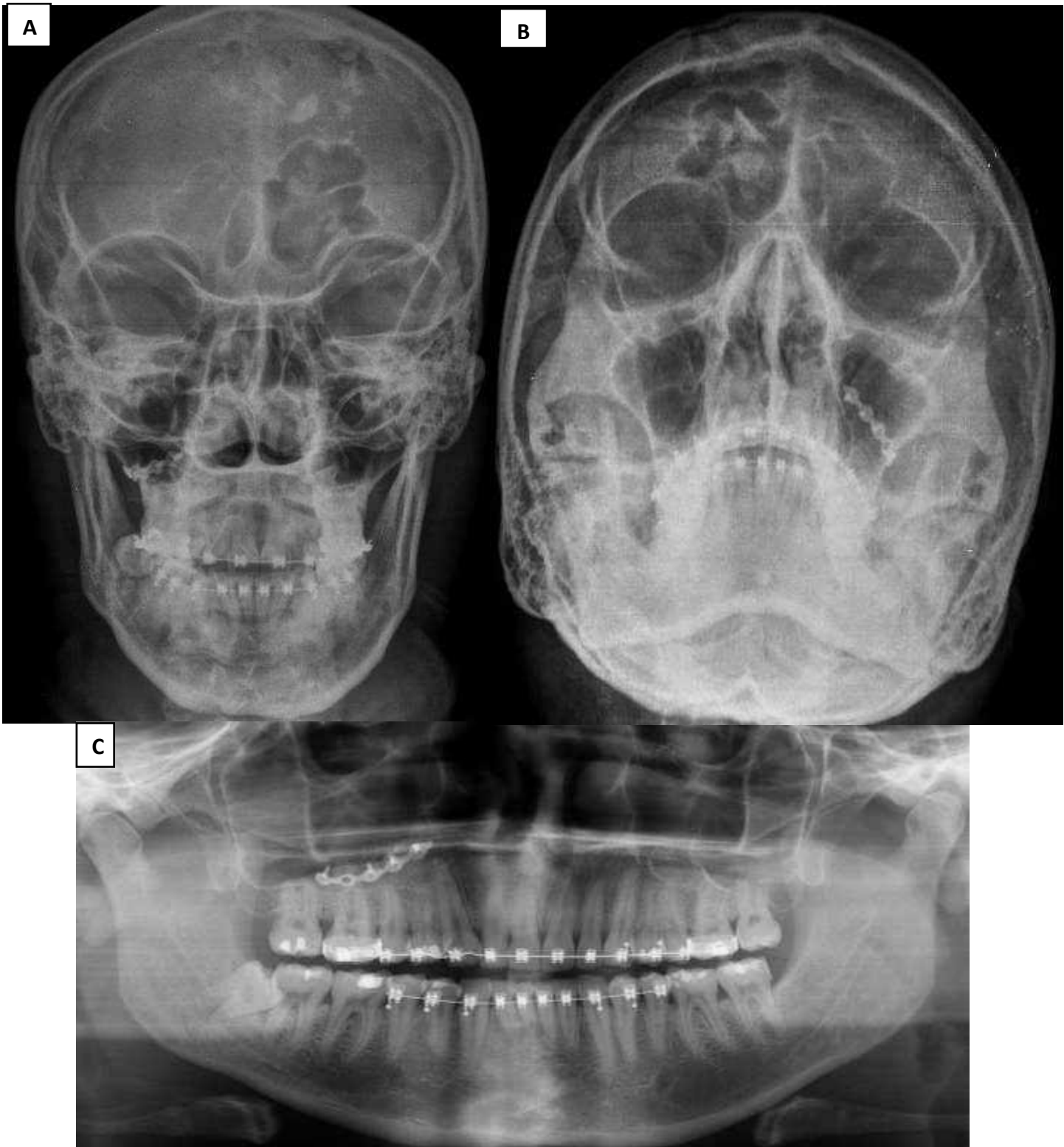


Figure-3



Attachments

TERMO DE AUTORIZAÇÃO DE USO DE IMAGEM E PUBLICAÇÃO DE CASO CLÍNICOEu Roberto Soares RG 12-817320

estou ciente da importância do uso de minha imagem e/ou caso clínico, especificados no Termo de Consentimento Livre e Esclarecido (TCLE) e relatado em prontuário médico, AUTORIZO, através do presente termo, os autores (Cristóvão Marcondes de Castro Rodrigues; Izabella Sol; Daniela Meneses Santos; Larissa Gonçalves Cunha Rios ; Jonas Dantas Batista; Flaviana Soares Rocha), do artigo intitulado **“Remoção de projétil de arma de fogo no seio maxilar- Relato de Caso”** a tirar as fotos que se façam necessárias e/ou relata meu caso em meios puramente acadêmico sem fins ou objetivos financeiros para ambas as partes.

Uberlândia - MG, 14 de Setembro de 2018.

Roberto Soares

Assinatura e liberação do Paciente

Transferência de Direitos Autorais

Declaro que, em caso de aceitação do artigo intitulado **“Remoção de projétil de arma de fogo no seio maxilar - Relato de Caso”**, a RGO - Revista Gaúcha de Odontologia passa a ter os direitos autorais a ele referentes, que se tornarão propriedade exclusiva da Revista vedada a qualquer reprodução, total ou parcial, em qualquer outra parte ou meio de divulgação, impressa ou eletrônica, sem que a prévia e necessária autorização seja solicitada e, se obtida, farei constar o competente agradecimento à Revista.

Nome do autor: Cristóvão Marcondes de Castro Rodrigues

Assinatura: Cristóvão Marcondes de Castro Rodrigues

Nome do autor: Izabella Sol

Assinatura: Izabella Sol

Nome do autor: Daniela Meneses Santos

Assinatura: Daniela Meneses Santos

Nome do autor: Larissa Gonçalves Cunha Rios

Assinatura: Larissa Gonçalves Cunha Rios

Nome do autor: Jonas Dantas Batista

Assinatura: Jonas Dantas Batista

Nome do autor: Flaviana Soares Rocha

Assinatura: Flaviana Soares Rocha

Uberlândia, 20 de novembro de 2018.

Transferência de Direitos Autorais

Declaro que, em caso de aceitação do artigo intitulado "**Remoção de projétil de arma de fogo no seio maxilar - Relato de Caso**", a **RGO - Revista Gaúcha de Odontologia** passa a ter os direitos autorais a ele referentes, que se tornarão propriedade exclusiva da Revista vedada a qualquer reprodução, total ou parcial, em qualquer outra parte ou meio de divulgação, impressa ou eletrônica, sem que a prévia e necessária autorização seja solicitada e, se obtida, farei constar o competente agradecimento à Revista.

Nome do autor: Cristóvão Marcondes de Castro Rodrigues

Assinatura: Cristóvão Marcondes de Castro Rodrigues

Nome do autor: Izabella Sol

Assinatura: Izabella Sol

Nome do autor: Daniela Meneses Santos

Assinatura: Daniela Meneses Santos

Nome do autor: Larissa Gonçalves Cunha Rios

Assinatura: Larissa Gonçalves Cunha Rios

Nome do autor: Jonas Dantas Batista

Assinatura: Jonas Dantas Batista

Nome do autor: Flávia Soares Rocha

Assinatura: Flávia Soares Rocha

Uberlândia, 20 de novembro de 2018.

Declaração de Responsabilidade:

Certifico que participei da concepção do trabalho intitulado "**Remoção de projétil de arma de fogo no seio maxilar - Relato de Caso**" para tornar pública minha responsabilidade pelo seu conteúdo, não omitindo quaisquer ligações ou acordos de financiamento entre os autores e companhias que possam ter interesse na publicação deste artigo; - Certifico que o manuscrito é original e que o trabalho, em parte ou na íntegra, ou qualquer outro trabalho com conteúdo substancialmente similar, de minha autoria, não foi enviado à outra Revista e não o será, enquanto sua publicação estiver sendo considerada pela **RGO - Revista Gaúcha de Odontologia**, quer seja no formato impresso ou no eletrônico.

Nome do autor: Cristóvão Marcondes de Castro Rodrigues

Assinatura: Cristóvão Marcondes de Castro Rodrigues

Nome do autor: Izabella Sol

Assinatura: Izabella Sol

Nome do autor: Daniela Meneses Santos

Assinatura: Daniela Meneses Santos

Nome do autor: Larissa Gonçalves Cunha Rios

Assinatura: Larissa Gonçalves Cunha Rios

Nome do autor: Jonas Dantas Batista

Assinatura: Jonas Dantas Batista

Nome do autor: Flávia Soares Rocha

Assinatura: Flávia Soares Rocha

Uberlândia, 20 de novembro de 2018.

<http://dx.doi.org/10.1590/1981-863720200002720180074>

| CLINICAL

Removal of firearm projectile from the maxillary sinus: a case report

Remoção de projétil de arma de fogo do seio maxilar: relato de caso

Cristóvão Marcondes de Castro **RODRIGUES**¹  <https://orcid.org/0000-0002-0590-9075>

Izabella **SOL**¹  <https://orcid.org/0000-0003-2384-9819>

Daniela **MENESES-SANTOS**¹  <https://orcid.org/0000-0002-8898-9508>

Larissa Gonçalves Cunha **RIOS**¹  <https://orcid.org/0000-0002-5385-7150>

Jonas Dantas **BATISTA**¹  <https://orcid.org/0000-0001-5649-6883>

Flaviana Soares **ROCHA**¹  <https://orcid.org/0000-0002-6759-2229>

ABSTRACT

Foreign bodies in the paranasal sinuses after critical accidents are rare occurrences that have sporadically been reported worldwide. Firearm projectiles, daggers, knives, glass fragments, stones, teeth, and wood can get lodged in the soft and hard tissues of the face. The management and prognosis in these cases depend on the composition and location of the foreign body as well as on the presence or absence of infection. Although there are reports involving the soft tissues of the face, the ethmoid, sphenoid, frontal, and maxillary sinuses are the most frequently involved sites. The main manifestation of this condition is sinusitis arising from infection and/or inflammation caused by the foreign body, which is a contaminated object. We report a case of removal of a firearm projectile located in the maxillary sinus of a 34-year-old patient under local anesthesia.

Indexing terms: Maxillary sinus. Maxillary sinusitis. Surgery, oral. Wounds, gunshot.